

Easy to understand reports  
facilitate treatment options.



**TOPA Diagnostics**  
351 East Rolling Oaks Drive, Suite 100  
Thousand Oaks, CA 91361  
805-373-8582  
CLIA Number 05D1022855

**Directors**  
Wayne M. Schultheis, M.D.  
Edward I. Blackman, M.D.  
Regina Singson, M.D.  
Jianming J. Yin, M.D.  
Danielle E. Westfall, M.D.

**ADDENDUM FINE NEEDLE ASPIRATION REPORT**

**PATIENT:** **PATIENT, YOUR** **PATH #:** **TF00-00001**  
D.O.B. 01/01/1946 AGE: 67 yrs SEX: F DATE COLLECTED: 01/01/2000  
PHYSICIAN: Code Doctor, M.D. DATE RECEIVED: 01/01/2000  
COPY TO: DATE REPORTED: 01/08/2013  
LOCATION: Physician Office

**DIAGNOSIS:**

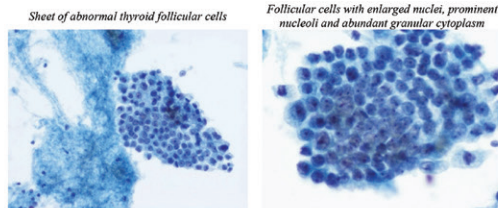
LEFT THYROID, FINE NEEDLE ASPIRATION:  
-Suspicious for follicular neoplasm, Hurthle cell type.

**MICROSCOPIC DESCRIPTION:**

Routine smears, ThinPrep, and cell block are cellular and demonstrate sheets of thyroid follicular cells with enlarged nuclei and prominent nucleoli. They have abundant granular cytoplasm. The findings are considered to be suspicious for a follicular neoplasm, Hurthle cell type. A differential consideration includes a dominant hyperplastic nodule with Hurthle cell metaplasia.

**COMMENT:** According to a recent consensus conference sponsored by the National Cancer Institute, a diagnosis of "suspicious for follicular neoplasm" is associated with a 15-30% risk of malignancy. Up to 35% will be non-neoplastic on excision. Usual follow-up consists of surgical excision (generally lobectomy). These are guidelines only; management should be based on the clinical situation of the individual patient. (Reference: Am J Clin Pathol 2009; 132: 655-657)

Based on the cytologic findings and reflex testing criteria, a sample will be submitted to Asuragen Laboratory for molecular testing. Results will be reported in an addendum report.



**CLINICAL HISTORY:** Not provided

**ANATOMIC SITE AND PROCEDURE:**

Left thyroid, fine needle aspiration

**GROSS DESCRIPTION:**

5 slide(s). Red translucent needle washing in CytoLyt solution. Received 1 RNA retain tube. 1 Thin prep slide prepared. 1 cell block prepared.

**Pathologist:** Wayne Schultheis, M.D.  
Electronically Signed

<b>ADDENDUM:</b>	<p><b>RESULTS OF THYROID MOLECULAR TESTING</b></p> <p><b>INTERPRETATION:</b> No DNA mutations or RNA translocations detected (performed at Asuragen lab)</p> <p><b>COMMENT:</b> According to recent literature, the overall risk of malignancy for a cytology diagnosed as FN/SFN (follicular neoplasm / suspicious for follicular neoplasm) with no mutations identified is 14%.</p> <p><b>Reference:</b> Nikiforov, Y. et al JCEM (2009), 94(6): 2092-2098</p> <p><b>Pathologist:</b> Wayne Schultheis, M.D. Electronically Signed</p>
------------------	--

Our reports use standardized formatting  
and terminology with color images that  
make them easy to comprehend and foster  
patient-physician communication.



351 Rolling Oaks Drive, Suite 100  
Thousand Oaks, CA 91361

Phone: 805.373.8582  
Fax: 805.373.0023  
Answering Service: 805.378.7761  
Email Client Services at: clientservice@topathology.com

[www.topathology.com](http://www.topathology.com)

©2016 TOPA Diagnostics. All rights reserved.

00000